

# Sendai Conference 2019



Zao Okama

2019.6.29 SAT 9:00 - 18:30

Venue: TKP Garden City Sendai  
(AER21F, 1-3-1 Chuo, Aoba-ku, Sendai)

## Co-sponsored by

Alexion Pharma Godo Kaisha,  
Biogen Japan Ltd. and Eisai Co., Ltd.  
Chugai Pharmaceutical Co., Ltd.,  
Novartis Pharma K.K. Medical Division and  
Takeda Pharmaceutical Co., Ltd.

Under the auspices of Japan Multiple Sclerosis Network

## Chairpersons

**Ichiro Nakashima**

Chairperson of the Board of Directors, Japan Multiple Sclerosis Network  
Professor, Department of Neurology, Tohoku Medical and Pharmaceutical University

**Kazuo Fujihara**

Professor, Department of Multiple Sclerosis Therapeutics, Fukushima Medical University  
Research Institute for Neuroscience



Sendai Conference 2018

Secretariat of Sendai Conference 2019  
c/o Keiso Shobo Publishing Co., Ltd.  
2-1-1 Suido, Bunkyo-ku, Tokyo 112-0005 Japan  
E-mail: sendai-conference@keiso-comm.com

 NPO法人  
日本多発性硬化症ネットワーク  
JAPAN MULTIPLE SCLEROSIS NETWORK

 ALEXION®

 CHUGAI  
A member of the Daiichi Sankyo Group

 NOVARTIS

 Takeda

## Sendai Conference 2019

Date : 29<sup>th</sup> June, 2019

Venue : Hall 21C, TKP Garden City Sendai (AER 21F, 1-3-1 Chuo, Aobaku, Sendai)

### Time Schedule

9 : 00	Opening Remarks
9 : 10	Oral session 1
10 : 25	Sponsored Session 1 (Sponsored by Chugai Pharmaceutical Co., Ltd.)
11 : 25	Coffee Break
11 : 35	Sponsored Session 2 (Supported by Takeda Pharmaceutical Co., Ltd.)
12 : 35	Lunch & Poster viewing
13 : 20	Clinical Trial Session
13 : 50	Sponsored Session 3 (Sponsored by Alexion Pharma Godo Kaisha)
14 : 50	Coffee Break
15 : 00	Oral Session 2
16 : 00	Sponsored Session 4 (Sponsored by Biogen Japan Ltd. and Eisai Co., Ltd.)
17 : 00	Coffee Break
17 : 10	Sponsored Session 5 (Sponsored by Novartis Pharma K.K. Medical Division)
18 : 10	Closing Remarks
18 : 20	Photo Session
18 : 30	Reception Dinner (& Award ceremony)

## Program

Date : 29th June, 2019

Venue : Hall 21C, TKP Garden City Sendai (AER 21F, 1-3-1 Chuo, Aobaku, Sendai)

- 9 : 00            Opening Remarks  
-9 : 10           OR     Dr. Kazuo Fujihara
- 9 : 10            Oral session 1 (Chairs : Drs. Kazumasa Yokoyama & Tomoko Okamoto)  
-10 : 25           OS1-1 Dr. Kimihiko Kaneko (Miyagi Hospital)  
                    Two cases of MOG-IgG-positive disease associated with CNS herpes simplex virus infection  
                    OS1-2 Dr. Hirohiko Ono (Tohoku University)  
                    T cell response to myelin oligodendrocyte glycoprotein (MOG) in patients with anti-MOG antibody  
                    OS1-3 Dr. Munenori Oyama (Keio University)  
                    Successful intravenous immunoglobulin and azathioprine treatment in a pediatric case of MOG-antibody-associated encephalomyelitis refractory to corticosteroids  
                    OS1-4 Dr. Yoshiki Takai (Tohoku University)  
                    Myelin oligodendrocyte glycoprotein antibody-associated disease : an immunopathological study  
                    OS1-5 Dr. Fumitaka Shimizu (Yamaguchi University)  
                    Blood-brain barrier-activation in anti-myelin oligodendrocyte glycoprotein antibody associated disorders
- 10 : 25           Sponsored Session 1 (Chair : Dr. Izumi Kawachi)  
-11 : 25           SS-1    Dr. Vanda Lennon (Mayo Clinic)  
                    Recent Advances in Understanding the Evolution of CNS Lesions in AQP4 Autoimmunity  
                    (Sponsored by Chugai Pharmaceutical Co., Ltd.)
- 11 : 25           Coffee Break  
-11 : 35
- 11 : 35           Sponsored Session 2 (Chair : Dr. Takayuki Kondo)  
-12 : 35           SS-2    Dr. Scott Zamvil (UCSF)  
                    Aquaporin-4-specific T cells and gut microbiota in neuromyelitis optica  
                    (Sponsored by Takeda Pharmaceutical Co., Ltd.)
- 12 : 35           Lunch & Poster viewing  
-13 : 20

- 13 : 20 Clinical Trial Session (Chair : Jin Nakahara)
- 13 : 50 CS-1 Dr. Katsuichi Miyamoto (Kindai University)  
Efficacy and safety of satralizumab (SA237) as add-on therapy for NMOSD : Results of Phase 3 study including subgroup analyses of Asian-region patients
- CS-2 Dr. Kazuo Fujihara (Fukushima Medical University)  
Efficacy and safety of eculizumab in aquaporin-4 antibody positive (AQP4-IgG+) neuromyelitis optica spectrum disorder (NMOSD) : a phase 3, randomized, double-blind, placebo-controlled, multicenter trial (PREVENT)
- 13 : 50 Sponsored Session 3 (Chair : Dr. Masaaki Niino)
- 14 : 50 SS-3 Dr. Patrick Waters (University of Oxford)  
AQP4 IgG: production, detection and destruction  
(Sponsored by Alexion Pharm Godo Kaisha)
- 14 : 50 Coffee Break
- 15 : 00
- 15 : 00 Oral Session 2 (Chairs : Drs. Takashi Ohashi & Tatsuro Misu)
- 16 : 00 OS2-1 Dr. Davide Cossu (Juntendo University)  
Modulation of experimental autoimmune encephalomyelitis by *Mycobacterium avium* subsp. *Paratuberculosis* or by BCG
- OS2-2 Dr. Ryouhei Komaki (NCNP Hospital)  
Cognitive impairments and regional brain volume in multiple sclerosis and neuromyelitis optica spectrum disorder : a cross-sectional observational study
- OS2-3 Dr. Fumitaka Sato (Kindai University)  
Altered microbiota could affect distinct CNS immune gene expressions in the Theiler's virus model of MS
- OS2-4 Dr. Aiko Isami (Niigata University)  
CSF-derived circulating cell-free DNA as a diagnostic biomarker : learning from a patient with multiphasic tumefactive lesions of the CNS during three years
- 16 : 00 Sponsored Session 4 (Chair : Dr. Hikoaki Fukaura)
- 17 : 00 SS-4 Dr. Heinz Wiendl (Muenster University)  
Learning MS immunopathogenesis via therapeutic interventions : novel insights  
(Sponsored by Biogen Japan Ltd. and Eisai Co., Ltd.)
- 17 : 00 Coffee Break
- 17 : 10

- 17 : 10 Sponsored Session 5(Chair : Dr. Juichi Fujimori)
- 18 : 10 SS-5 Dr. Iris-Katharina Penner(Heinrich Heine University Düsseldorf, Department of Neurology & Cogito Center for Applied Neurocognition and Neuropsychological Research, Düsseldorf, Germany)  
Cognitive impairment in multiple sclerosis and its measurement in daily clinical practice  
(Sponsored by Novartis Pharma K.K. Medical Division)
- 18 : 10 Closing Remarks  
CR Dr. Ichiro Nakashima
- 18 : 20 Photo Session
- 18 : 30 Reception Dinner(& Award ceremony)

-----  
Poster Session(Venue : Hall 21D)

- P-1 Dr. Ryotaro Ikeguchi(Tokyo Women's Medical University)  
Programmed death 1(PD-1)inhibitor-associated myasthenia gravis with necrotizing myopathy and myocarditis : case report and literature review
- P-2 Dr. Mio Hamatani(Kyoto University)  
Immunosuppressive Role of Sulfatide in The Pathogenesis of Multiple Sclerosis
- P-3 Dr. Hideaki Mashimo(Tokyo Metropolitan Neurological Hospital)  
An undiagnosed case of childhood-onset recurrent demyelinating or inflammatory brainstem lesions
- P-4 Dr. Shohei Beppu(Osaka University)  
Serum Sema4A levels correlate with distinct clinical phenotype in patients with NMOsd
- P-5 Dr. Yuji Tomizawa(Juntendo Tokyo Koto Geriatric Medical Center)  
A case of bilateral hypothalamic lesions with anti-NAE autoantibodies
- P-6 Dr. Takeshi Araki(Kobe University)  
Long-term follow-up of a patient with anti-MOG antibody seropositive treated by steroid over 10 years
- P-7 Dr. Ayako Koguchi(The University of Tokyo)  
An elevated GFAP level revealing MRI-undetected NMO relapse with truncal pruritus and paresthesia
- P-8 Dr. Ryuhei Harada(Tokyo Metropolitan Neurological Hospital)  
Lhermitte's sign due to thoracic spinal cord lesion in neuromyelitis optica
- P-9 Dr. Satoru Oji(Saitama Medical University)  
A case of anti-MOG antibody positive neurological disease, mimicking neuromyelitis optica spectrum disorders - comparison of clinical feature between AQP4 and MOG antibody positive cases -

- P-10 Dr. Asako Tagawa(Hiratsuka City Hospital)  
A 70-year old female case of possible clinically isolated syndrome(CIS) successfully treated with corticosteroid and plasma pheresis
- P-11 Dr. Keita Takahashi(Yokohama City University)  
Anti-myelin oligodendrocyte glycoprotein antibody-positive neuromyelitis optica spectrum disorder manifested by switching to dimethyl fumarate
- P-12 Dr. Nami Tanaka(Doshisha University)  
Identification of therapeutic target of Multiple Sclerosis through MALDI-Imaging Mass Spectrometry(IMS)for Experimental Autoimmune Encephalomyelitis(EAE) mouse spinal cords and brains
- P-13 Dr. Ryohei Ohtani(JR Tokyo general hospital)  
Exosomal microRNA profiles from cerebrospinal fluid in neuromyelitis optica spectrum disorders

## OS1-1 Two cases of MOG-IgG-positive disease associated with CNS herpes simplex virus infection

Kimihiko Kaneko<sup>1,2</sup>, Douglas Kazutoshi Sato<sup>2,3</sup>, Toshiyuki Takahashi<sup>2,4</sup>, Ryo Ogawa<sup>2</sup>, Yoshiki Takai<sup>2</sup>, Shuhei Nishiyama<sup>2</sup>, Tatsuro Misu<sup>2</sup>, Hiroshi Kuroda<sup>2</sup>, Ryosuke Sato<sup>5</sup>, Osamu Kobayashi<sup>5</sup>, Satoru Tanaka<sup>6</sup>, Kyoichi Nomura<sup>6</sup>, Ichiro Nakashima<sup>2,7</sup>, Kazuo Fujihara<sup>2,8,9</sup>, Masashi Aoki<sup>2</sup>

<sup>1</sup> Department of Neurology, NHO Miyagi National Hospital, Yamamoto, Watari, Miyagi, Japan

<sup>2</sup> Department of Neurology, Tohoku University School of Medicine, Sendai, Miyagi, Japan

<sup>3</sup> Brain Institute and Hospital Sao Lucas Pontifical Catholic University of Rio Grande do Sul, Port Alegre, Brazil

<sup>4</sup> Department of Neurology, NHO Yonezawa National Hospital, Yonezawa, Yamagata, Japan

<sup>5</sup> Department of Pediatrics, Oita Medical University, Yufu, Oita, Japan

<sup>6</sup> Department of Neurology, Saitama Medical Center, Kawagoe, Saitama, Japan

<sup>7</sup> Department of Neurology, Tohoku Medical and Pharmaceutical University, Sendai, Miyagi, Japan

<sup>8</sup> Multiple Sclerosis and Neuromyelitis Optica Center, TOHOKU Research Institute for Neuroscience, Koriyama, Fukushima, Japan

<sup>9</sup> Department of Neurology, Fukushima Medical University, Fukushima, Japan

### Background

Herpes simplex virus (HSV) infection can be associated with autoantibody-associated neurological diseases such as N-methyl-D-aspartate receptor (NMDAR) encephalitis, but its association with myelin oligodendrocyte glycoprotein (MOG)-IgG+ disease is not known.

### Objective

To survey an association between MOG-IgG+ disease and HSV infection in our clinical database of 399 Japanese MOG-IgG+ cases collected from September 2015 to December 2017.

### Result

We found 2 MOG-IgG-positive cases with central nervous system (CNS) HSV infection. (Case 1) A 49-year-old woman developed generalized convulsive seizure after general fatigue. Cerebrospinal fluid (CSF) showed pleocytosis (42/μl), elevated levels of protein (127mg/dl) and myelin basic protein (MBP) (347pg/ml). HSV-PCR in CSF was positive at that time. Brain MRI showed asymmetrical lesions in bilateral orbitofrontal cortex, cingulate gyrus and medial temporal lobe. Acyclovir (ACV) and intravenous methylprednisone (IVMP) were started but not so effective. One month later, brain MRI revealed the spread of the lesions into the insula cortex. MOG-IgG was positive in the serum, but NMDAR antibody and HSV-PCR in CSF were negative. Additional IVMP and plasmapheresis were done, but such sequelae as

memory loss and gait disturbance remained.(Case 2)a 5-year-old healthy boy developed low-grade fever, disturbance of consciousness and bowel-bladder dysfunction which progressed for a week. CSF showed pleocytosis, elevated levels of protein(73 mg/dl)and MBP(15,184 pg/ml). Brain and spine MRI showed disseminated subcortical white matter lesions and longitudinally extensive spinal lesions. MOG-IgG was positive both in the serum and CSF. HSV-PCR in CSF was also positive, but CSF-NMDAR was negative. He was treated with IVMP and ACV, which lead to a complete resolution of the lesions.

### **Discussion**

In HSVE, secondary autoantibody production occasionally occurs. The two cases in this study suggests that MOG-IgG might have been produced in association with CNS HSV infection. Interestingly, the main clinical pictures and MRI findings in the two cases were different, that is, those of HSVE in Case 1 and acute disseminated encephalitis in Case 2.

### **Conclusion**

MOG-IgG-positive disease may occasionally be associated with CNS HSV infection.



## OS1-2 T cell response to myelin oligodendrocyte glycoprotein (MOG) in patients with anti-MOG antibody

Hirohiko Ono<sup>1</sup>, Tatsuro Misu<sup>2</sup>, Yoshiki Takai<sup>1</sup>, Shuhei Nishiyama<sup>1</sup>, Hiroshi Kuroda<sup>1</sup>, Toshiyuki Takahashi<sup>1,3</sup>, Ichiro Nakashima<sup>4</sup>, Kazuo Fujihara<sup>5</sup>

<sup>1</sup> Department of Neurology, Tohoku University Graduate School of Medicine, <sup>2</sup> Department of Multiple Sclerosis Therapeutics, Tohoku University Graduate School of Medicine, <sup>3</sup> Department of Neurology, Yonezawa National Hospital, <sup>4</sup> Department of Neurology, Tohoku Medical and Pharmaceutical University, <sup>5</sup> Department of Multiple Sclerosis Therapeutics, Fukushima Medical University School of Medicine

**Background** : T cells play key role for the antibody-mediated destruction of astrocytes in anti-aquaporin 4 (AQP4) antibody (ab)+ neuromyelitis optica (NMO). Recently, anti-myelin oligodendrocyte glycoprotein (MOG) ab was discovered in central nervous system (CNS) inflammatory diseases including acute disseminated encephalomyelitis, optic neuritis, NMO and cortical encephalitis. However, the role of T cells in MOG-ab associated CNS inflammatory diseases is still unknown. Here, we analyzed the T cell response to CNS myelin peptides in MOG-ab associated CNS inflammatory diseases.

**Methods** : Peripheral blood mononuclear cells (PBMCs) were obtained from 18 MOG-ab+ patients, 17 AQP4-ab+ patients and 10 healthy controls (HC). PBMCs were cultured with one of 14 overlapping peptides of MOG or 5 peptides of AQP4 or 2 peptides of myelin basic protein (MBP) or 2 peptides of proteolipid protein (PLP). CD69 expression on CD4 T cells was analyzed using flow cytometer and T cell responses to CNS peptides were evaluated.

**Results** : T-cell response to MOG p16-40 in MOG-ab+ patients was significantly different from HC ( $p = 0.03$ ). T-cell response to AQP4 peptides (p21-40, p61-80, 131-150, p211-230) and MOG p16-40, p61-85, p136-160, p196-218 in AQP4-ab+ patients was significantly increased compared with HC ( $p = 0.02, 0.03, 0.02, 0.02, 0.02, 0.01, 0.01, 0.03$ , respectively). T-cell response to AQP4 peptides in AQP4-ab+ patients was significantly increased compared with MOG-ab+ patients.

**Conclusion** : T cells from MOG-ab+ patients responded against MOG peptides, while T cells from AQP4-ab+ patients mainly responded against AQP4 but also responded MOG peptides.

### **OS1-3 Successful intravenous immunoglobulin and azathioprine treatment in a pediatric case of MOG-antibody-associated encephalomyelitis refractory to corticosteroids**

Munenori Oyama<sup>1</sup>, Yoshikane Izawa<sup>1</sup>, Kenji Kufukihara<sup>1</sup>, Toshiyuki Takahashi<sup>2</sup>, Jin Nakahara<sup>1</sup>

<sup>1</sup> Department of Neurology, Keio University School of Medicine, Tokyo, Japan.

<sup>2</sup> Department of Neurology, Tohoku University Graduate School of Medicine, Miyagi, Japan.

Antibodies against myelin oligodendrocyte glycoprotein (MOG) have been suggested to play a role in a subset of patients with optic neuritis, encephalitis, and myelitis. While corticosteroids are generally considered to be effective both as acute and maintenance therapy for MOG-antibody-associated diseases, treatment strategy for steroid-refractory cases is poorly standardized. Here we report a pediatric case of steroid-refractory MOG-antibody-associated encephalomyelitis successfully treated with intravenous immunoglobulin (IVIg) with maintenance immunosuppression with azathioprine (AZP). A 14 years old girl developed progressive sensory disturbance in her right upper extremity and about a month later, she developed epileptic seizure attacks and hospitalized for evaluation. During the hospitalization, her symptoms further progressed and developed various neurological deficits including diplopia, bladder and bowel dysfunctions, and paraplegia. MRI studies revealed multiple T2 lesions in her brain and spinal cord suggestive of encephalomyelitis. Together with the seropositivity of anti-MOG-antibodies, she was diagnosed as having MOG-antibody-associated encephalomyelitis. Repeated intravenous methylprednisolone (IVMP) only showed modest efficacy, whereas IVIg successfully resolved the majority of her symptoms. Prevention of relapses failed with moderate dose of prednisolone alone, but no further relapse occurred with the concomitant immunosuppression using AZP. Our case suggests that IVIg and AZP could be utilized as second-line treatment options for MOG-antibody-associated diseases.

## OS1-4 Myelin oligodendrocyte glycoprotein antibody-associated disease : an immunopathological study

Yoshiki Takai, MD, PhD<sup>1</sup> ; Tatsuro Misu, MD, PhD<sup>1,2</sup> ; Kimihiko Kaneko, MD, PhD<sup>1,3</sup> ; Norio Chihara, MD, PhD<sup>4</sup> ; Koichi Narikawa, MD, PhD<sup>5</sup> ; Satoko Tsuchida, MD, PhD<sup>6</sup> ; Hiroya Nishida, MD<sup>7</sup> ; Takashi Komori, MD, PhD<sup>8</sup> ; Morinobu Seki, MD, PhD<sup>9</sup> ; Teppei Komatsu, MD, PhD<sup>10</sup> ; Kiyotaka Nakamagoe MD, PhD<sup>11</sup> ; Toshimasa Ikeda, MD<sup>12</sup> ; Mari Yoshida, MD, PhD<sup>12</sup> ; Toshiyuki Takahashi, MD, PhD<sup>13</sup> ; Hirohiko Ono, MD<sup>1</sup> ; Shuhei Nishiyama, MD, PhD<sup>1</sup> ; Hiroshi Kuroda, MD, PhD<sup>1</sup> ; Ichiro Nakashima, MD, PhD<sup>14</sup> ; Hiroyoshi Suzuki, MD, PhD<sup>15</sup> ; Monika Bradl, PhD<sup>16</sup> ; Hans Lassmann, MD, PhD<sup>16</sup> ; Kazuo Fujihara, MD, PhD<sup>1,17</sup> ; Masashi Aoki, MD, PhD<sup>1</sup>

From the <sup>1</sup>Department of Neurology, Tohoku University Graduate School of Medicine, Sendai, Miyagi, Japan ; <sup>2</sup>Department of Multiple Sclerosis Therapeutics, Tohoku University Graduate School of Medicine, Sendai, Miyagi, Japan ; <sup>3</sup>Department of Neurology, National Hospital Organization Miyagi National Hospital, Watari, Miyagi, Japan ; <sup>4</sup>Division of Neurology, Kobe University Graduate School of Medicine, Kobe, Hyogo, Japan ; <sup>5</sup>Department of Neurology, Japanese Red Cross Ishinomaki Hospital, Ishinomaki, Miyagi, Japan ; <sup>6</sup>Department of Pediatrics, Japanese Red Cross Akita Hospital, Akita, Akita, Japan ; <sup>7</sup>Department of Neuropediatrics, Tokyo Metropolitan Neurological Hospital, Fuchu, Tokyo, Japan ; <sup>8</sup>Department of Laboratory Medicine and Pathology, Tokyo Metropolitan Neurological Hospital, Fuchu, Tokyo, Japan ; <sup>9</sup>Department of Neurology, Keio University School of Medicine, Shinjuku-ku, Tokyo, Japan ; <sup>10</sup>Department of Neurology, the Jikei University School of Medicine, Minato-ku, Tokyo, Japan ; <sup>11</sup>Department of Neurology, Division of Clinical Medicine, Faculty of Medicine, University of Tsukuba, Tsukuba, Ibaraki, Japan ; <sup>12</sup>Department of Neuropathology, Institute for Medical Science of Aging, Aichi Medical University, Nagakute, Aichi, Japan ; <sup>13</sup>Department of Neurology, National Hospital Organization Yonezawa National Hospital, Yonezawa, Yamagata, Japan ; <sup>14</sup>Department of Neurology, Tohoku Medical and Pharmaceutical University, Sendai, Miyagi, Japan ; <sup>15</sup>Department of Pathology, National Hospital Organization Sendai Medical Center, Sendai, Miyagi, Japan ; <sup>16</sup>Department of Neuroimmunology, Center for Brain Research, Medical University of Vienna, Vienna, Austria ; <sup>17</sup>Department of Multiple Sclerosis Therapeutics, Fukushima Medical University, Fukushima, Fukushima, Japan.

### Background

Conformation-sensitive antibodies against myelin oligodendrocyte glycoprotein (MOG) are detectable in patients with optic neuritis, neuromyelitis optica spectrum disorders (NMOSD), acute or multiphasic disseminated encephalomyelitis (ADEM/MDEM) and brainstem/cerebral cortical encephalitis etc, but are

rarely detected in prototypic multiple sclerosis (MS). Among brain biopsies of patients with MOG antibody-associated diseases (MOGAD), there were some demyelinating plaques with complement deposition, suggesting humoral immune-mediated demyelination (MS pathology pattern II). However, detailed analysis of the demyelinating characteristics and the relationship with humoral immune factors in MOGAD has not been made.

### **Objective**

To clarify the pathological features of MOGAD.

### **Methods**

We immunohistochemically analyzed several inflammatory demyelinating diseases and compared them with biopsied brain tissues from 11 patients with MOGAD.

### **Results**

The patients' median age at onset was 29 years (range 9-64) and the median interval from attack to biopsy was 1 (range 0.5-96) month. The clinical diagnoses were ADEM (n=2), MDEM (n=1), multiple brain lesions without encephalopathy (n=3), leukoencephalopathy (n=3) and cortical encephalitis (n=2). Pathologically, the majority of demyelinating plaques showed ADEM-like perivenous demyelinating pattern (91.6% : 153/167 lesions) or fusion-pattern (6.6%) and only three lesions (1.8%) showed MS-like confluent demyelinated plaques. In MOGAD, 37% of the demyelinating plaques showed MOG-dominant myelin loss. Perivascular cuffing were mainly consisted of macrophages (CD68 ;  $1814 \pm 1188$  cells/mm<sup>2</sup>) and T cells (CD3 ;  $2286 \pm 1951$  cells/mm<sup>2</sup>), with CD4-dominancy (CD4+ vs CD8+ ;  $1281 \pm 1196$  cells/mm<sup>2</sup> vs  $851 \pm 762$  cells/mm<sup>2</sup>, P<0.01), while B cell infiltration was milder (CD20 ;  $468 \pm 817$  cells/mm<sup>2</sup>). The humoral immunity such as perivascular deposits of activated complement was occasionally observed in some MOGAD demyelinating lesions, but the frequency was quite lower than that observed in NMOSD.

### **Conclusions**

ADEM-like perivenous inflammatory demyelination with MOG-dominant myelin loss was the characteristic finding in acute phase of MOGAD. These pathological features were clearly different from MS and NMOSD, suggesting that MOGAD is an independent autoimmune demyelinating disease entity.

## OS1-5 Blood-brain barrier-activation in anti-myelin oligodendrocyte glycoprotein antibody associated disorders

Fumitaka Shimizu<sup>1</sup>, Ryo Ogawa<sup>2</sup>, Kanako Hara<sup>1</sup>, Toshiyuki Takahashi<sup>2</sup>, Yukio Takeshita<sup>1</sup>, Tatsuro Misu<sup>2</sup>, Yasuteru Sano<sup>1</sup>, Toshihiko Maeda<sup>1</sup>, Susumu Fujikawa<sup>1</sup>, Ichiro Nakashima<sup>2,3</sup>, Kazuo Fujihara<sup>2,4</sup> and Takashi Kanda<sup>1</sup>

<sup>1</sup> Department of Neurology and Clinical Neuroscience, Yamaguchi University Graduate School of Medicine, Ube, Japan

<sup>2</sup> Department of Neurology, Tohoku University Graduate School of Medicine, Sendai, Japan

<sup>3</sup> Department of Neurology, Tohoku Medical and Pharmaceutical University, Sendai, Japan

<sup>4</sup> Department of Multiple Sclerosis Therapeutics, Fukushima Medical University, Fukushima, Japan

**Background** : Breakdown of the blood-brain barrier (BBB) is a key pathological feature of multiple sclerosis and neuromyelitis optica (NMO). We previously reported the effect of sera from MS and NMO patients on the BBB dysfunction and the association between BBB dysfunction and glucose-regulated protein 78 (GRP 78) autoantibodies in NMO. It is still unclear whether BBB disruption is associated with pathomechanism of anti-myelin oligodendrocyte glycoprotein antibodies (MOG-Abs) associated disorders.

**Objective** : The purpose of this study is to clarify the effect of immunoglobulin G (IgG) from MOG patients on the BBB-endothelial cell activation. We observed the positivity of GRP78 antibodies in MOG-Abs associated disorders.

**Methods** : We purified IgG from sera with MOG-Abs associated disorders patients [15 sera in the acute phase (acute MOG), 14 sera in stable stage (stable MOG)]. MOG-Abs were detected using cell-based assay in Tohoku University. IgGs from 9 healthy and 27 disease controls were used as controls. IgG was exposed to the human brain microvascular endothelial cells (TY10) and the amount of nuclear NF- $\kappa$ B p65 positive cells as a marker of endothelial cell activation was analyzed using a high-content imaging system. Presence of GRP78 antibodies from patient IgGs was detected by western blots.

**Results** : IgG in acute MOG group significantly induced the nuclear translocation of NF- $\kappa$ B p65 compared to those from stable MOG group and healthy/disease control group. The rate of GRP78 antibody positivity observed in acute MOG groups (10/15, 66%) was significantly higher than that in the disease control groups (3/27, 11%) or the healthy control groups (0/9, 0%).

**Conclusion** : Endothelial cell activation induced by IgG incubation was observed in not only NMO patients but also MOG associated disorders patients. GRP78 antibodies may be associated with BBB dysfunction in MOG-Abs associated disorders.



## SS-1 Recent Advances in Understanding the Evolution of CNS Lesions in AQP4 Autoimmunity

Vanda A. Lennon, MD, PhD



Mayo Clinic Rochester MN, USA.

**Abstract** : AQP4-specific IgG targeting astrocytes causes severe relapsing CNS inflammation, prominently affecting spinal cord and optic nerves (NMO spectrum disorders). Myelin loss is secondary. AQP4 is concentrated at astrocyte end-feet embracing capillaries, glutamatergic synapses, nodes-of-Ranvier, ventricular walls and pia-glial interfaces. IgG binding to AQP4 stimulates astrocytic synthesis and secretion of complement components, cytokines and chemokines. A hallmark of established NMO lesions is loss of AQP4 and linked glutamate-transporters, and deposition of Ig and complement membrane-attack-complex in formerly AQP4-rich sites. Microglia are activated histopathologically, but their role in lesion evolution is unknown. We established a murine NMO model by continuously infusing patient-derived IgGs or monoclonal-IgG (AQP4-extracellular-domain-specific) into the spinal subarachnoid space. Both IgGs (without exogenous complement) induced motor impairment and NMO-consistent pathology in wild-type but not AQP4-null mice ; control IgGs had no effect. In vivo spinal cord imaging revealed striking physical interaction of microglia with astrocytes, without astrocyte death. In mice depleted of microglia, motor impairment and characteristic NMO immunohistopathology were abrogated. We demonstrated that early complement components mediate this astrocyte-microglia cross-talk. Previously, the only roles assigned to complement in NMO lesion evolution were chemotactic signaling and target cell lysis. Our findings identify microglia as a new target for NMO therapeutic interception.

## CURRICULUM VITAE

Dr. Lennon is Dorothy A. Adair Professor in the Departments of Immunology, Neurology and Laboratory Medicine at the Mayo Clinic in Rochester MN, and was named a Distinguished Alumnus of Mayo Clinic in 2018. She graduated in Medicine from the University of Sydney. Following residency in Internal Medicine at McGill University, Montreal, she completed a Ph.D. degree in Immunology at the Walter and Eliza Hall Institute in Melbourne and National Multiple Sclerosis Society Postdoctoral Fellowship at the Salk Institute in San Diego. There for 6 years she combined basic immunology and neurobiology studies, attaining adjunct appointments as Assistant Professor and Associate Professor in Neurosciences at the University of California, San Diego. In 1978 she established the Neuroimmunology Laboratory at Mayo Clinic, Rochester, bridging the Departments of Neurology and Immunology. In 2005 she established at Mayo Clinic the first Autoimmune Neurology Fellowship Program in North America. Her research and clinical translational activities continue to focus on cancer as a significant initiator of neurological autoimmunity, and neurotransmitter receptors, ion channels and other plasma membrane channels pertinent to autoimmunity, neurobiology and cancer biology.

Dr. Lennon is a member of the American Association of Immunologists, Society for Neuroscience, American Academy of Neurology, American Society for Neurochemistry, American Society for Clinical Investigation, Clinical Immunology Society, American Association of Medical Laboratory Immunologists, an inaugural member of the Federation of Clinical Immunology Societies, Honorary Member of the American Association of Neuromuscular and Electrodiagnostic Medicine and Honorary Fellow of the Neurological Society of Thailand and the Hong Kong Multiple Sclerosis Society.



## SS-2 Aquaporin-4-specific T cells and gut microbiota in neuromyelitis optica



Scott Zamvil

University California, San Francisco (UCSF)

Aquaporin-4 (AQP4)-specific antibodies are IgG1, a T cell-dependent isotype, indicating AQP4-specific T cells have a key role in neuromyelitis optica (NMO) pathogenesis. In my presentation, I will describe our research: (1) identifying AQP4-specific T cells in NMO patients, (2) evaluating the potential role of NMO gut microbiota in proinflammatory T cell polarization, and (3) use of mouse models to understand how AQP4-specific T cells may escape tolerance. Initially, we observed that proliferative AQP4-specific T cells in NMO patients are expanded and exhibit Th17 polarization, providing further support the role of Th17 cells in NMO. T cells recognizing an immunodominant AQP4 T cell epitope cross-reacted with a homologous sequence of a *Clostridium perfringens* ABC transporter, suggesting this commensal microbe might participate in NMO pathogenesis. A subsequent pilot gut microbiome study revealed overexpression of *C. perfringens* in NMO. Currently, we are evaluating how *C. perfringens* and other bacteria may influence the balance of Th17 and regulatory (Treg) cells.

Initial attempts to generate an in vivo AQP4-based NMO model in wild-type (WT) mice were not successful. Recently, it was observed that pathogenic AQP4-specific Th17 cells exist in AQP4-deficient mice, but not WT mice, and can cause clinical and histologic CNS autoimmunity. My laboratory has been investigating central (thymic) and peripheral mechanisms of tolerance to the ubiquitously expressed AQP4.

## CURRICULUM VITAE

### EDUCATION :

- 1979 B.A. Claremont Men's College (Chemistry)  
1986 Ph.D. Stanford Medical School (Medical Microbiology)  
1988 M.D. Stanford Medical School

### POSTGRADUATE TRAINING :

- 1989 Intern, Internal Medicine, Pacific Presbyterian Medical Center, San Francisco, CA  
1990 Resident, Internal Medicine, Stanford University Medical Center, Palo Alto, CA  
1990 – 1993 Resident, Neurology, Brigham and Women's Hospital, Boston, MA

### LICENSURE :

- 1989 California Medical License, Registration No. G 66283 (Active)  
1990 Massachusetts Medical License, Registration No. 73043  
1999 American Board of Psychiatrists and Neurologists, Certification in Adult Neurology, Registration No. 47196 (Active)

### ACADEMIC APPOINTMENTS :

- 1993 – 1994 Instructor in Neurology, Harvard Medical School  
1994 – 1998 Assistant Professor in Neurology, Harvard Medical School  
1998 – 2004 Assistant Professor of Neurology (Adjunct), UCSF  
2004 – 2010 Associate Professor of Neurology (in Residence), UCSF  
2010 – present Professor of Neurology (in Residence) UCSF  
2004 – present Faculty Member, Program in Immunology, UCSF  
2004 – present Faculty Member, Biomedical Sciences Graduate Program, UCSF  
2007 – present Faculty Member, Program in Biological Sciences, UCSF

### HOSPITAL APPOINTMENTS :

- 1993 – 1996 Associate Physician in Medicine (Neurology), Brigham and Women's Hospital  
1996 – 1998 Associate Neurologist, Brigham and Women's Hospital  
1997 – 1998 Clinical Associate Staff (Neurology), Massachusetts General Hospital  
1998 – present Attending Physician (Neurology), University of California, San Francisco, Moffett-Long Hospitals  
1998 – 2000 Attending Physician (Neurology), UCSF/Mt. Zion Hospital (MS Clinic)

### HONORS AND AWARDS

- 1979 Summa cum laude  
1979 Department Honor's in Chemistry  
1994 – 1999 Harry Weaver Neuroscience Scholar, National Multiple Sclerosis Society  
1994 – 2000 Clinician Investigator Development Award (NIH)  
2001 – 2005 First Independent Investigator Award (NIH, awarded 2000)  
2002 Atorvastatin Research Award  
2002 Boehringer Ingelheim Research Award (Federation of Clinical Immunology Societies (FOCIS) for EAE statin research)  
2003 Fellow, American Neurological Association (FANA)  
2009 Fellow, American Academy of Neurology (FAAN) (elected 10/09)  
2014 Donnie Smith Chair in Multiple Sclerosis Research

## CS-1 Efficacy and safety of satralizumab(SA237) as add-on therapy for NMOSD : Results of Phase 3 study including subgroup analyses of Asian-region patients

Katsuichi Miyamoto

Department of Neurology, Kindai University School of Medicine

### Introduction

Interleukin-6(IL-6)is involved in the pathophysiology of neuromyelitis optica spectrum disorder (NMOSD), a crippling disease of the central nervous system caused by severe relapses of optic neuritis and myelitis. Satralizumab(SA237)is a recycling humanized monoclonal antibody targeting the IL-6 receptor.

We report efficacy and safety results of satralizumab in overall and in Asian-region(Asian-R)patients of the SAKuraSky study, a Phase 3 double-blind, placebo-controlled, add-on study in patients with NMOSD (NCT02028884).

### Methods

83 patients who meet established diagnostic criteria for NMOSD with or without anti-AQP4-Ab were randomized to receive satralizumab(120 mg)subcutaneously or placebo at week 0, 2 and 4 and every 4 weeks thereafter, in addition to stable baseline immunosuppressant including corticosteroids. The primary endpoint was time to first protocol-defined relapse(PDR). Anti-AQP4-Ab serostatus and Asian-R(Japan and Taiwan vs. Others)subgroup analyses were conducted as pre-specified subgroup analyses.

### Results

Satralizumab significantly reduced the risk of experiencing a PDR in NMOSD patients by 62% vs placebo ; hazard ratio(HR), 0.38 ; 95% confidence interval(CI), 0.16-0.88 ;  $p=0.0184$ , in addition to baseline immunosuppressant including corticosteroids in the overall population(83 patients). The pre-defined subgroup analysis demonstrated a 79% PDR risk reduction with satralizumab vs placebo in anti-AQP4-Ab positive patients(HR, 0.21 ; 95% CI, 0.06–0.75)and 34% in anti-AQP4-Ab negative patients(HR, 0.66 ; 95% CI, 0.20–2.24). Satralizumab showed 85% risk reduction of PDR compared to placebo in the Asian-R(34 patients)subgroup(HR, 0.15 ; 95% CI, 0.02-1.23). The safety profile of Asian-R in the double-blind period was comparable with the overall population, with no deaths or anaphylactic reactions.

### Conclusions

Treatment with satralizumab as add-on to baseline immunosuppressant therapy reduced the risk of PDR in NMOSD patients, with a favorable safety profile in overall and Asian-R patients.

## **CS-2 Efficacy and safety of eculizumab in aquaporin-4 antibody positive (AQP4-IgG+) neuromyelitis optica spectrum disorder (NMOSD) : a phase 3, randomized, double-blind, placebo-controlled, multicenter trial (PREVENT)**

Kazuo Fujihara

Tohoku University Graduate School of Medicine, Sendai, Japan

Fukushima Medical University School of Medicine, Fukushima City, Japan

Southern TOHOKU Research Institute for Neuroscience, Koriyama, Japan

Sean J Pittock,<sup>1</sup> Achim Berthele,<sup>2</sup> Ho Jin Kim,<sup>3</sup> Michael Levy,<sup>4,5</sup>

Jacqueline Palace,<sup>6</sup> Ichiro Nakashima,<sup>7,8</sup> Murat Terzi,<sup>9</sup> Natalia Totolyan,<sup>10</sup> Shanthi Viswanathan,<sup>11</sup>

Kai-Chen Wang,<sup>12,13</sup> Róisín Armstrong,<sup>14</sup> Kenji P Fujita,<sup>14</sup> Amy Pace,<sup>14</sup> Dean M Wingerchuk<sup>15</sup>

<sup>1</sup> Mayo Clinic, Rochester, MN, USA

<sup>2</sup> Technical University of Munich, Munich, Germany

<sup>3</sup> Research Institute and Hospital of National Cancer Center, Goyang, South Korea

<sup>4</sup> Johns Hopkins University, Baltimore, MD, USA

<sup>5</sup> Massachusetts General Hospital and Harvard Medical School, Boston, MA, USA

<sup>6</sup> John Radcliffe Hospital, Oxford, UK

<sup>7</sup> Tohoku University Graduate School of Medicine, Sendai, Japan

<sup>8</sup> Tohoku Medical and Pharmaceutical University, Sendai, Japan

<sup>9</sup> Ondokuz Mayıs University, Samsun, Turkey

<sup>10</sup> First St. Petersburg State Medical University n.a. I.P. Pavlov, St. Petersburg, Russia

<sup>11</sup> Kuala Lumpur Hospital, Kuala Lumpur, Malaysia

<sup>12</sup> Cheng-Hsin General Hospital, Taipei, Taiwan

<sup>13</sup> National Yang Ming University, Taipei, Taiwan

<sup>14</sup> Alexion Pharmaceuticals, Boston, MA, USA

<sup>15</sup> Mayo Clinic, Scottsdale, AZ, USA

### **Objective**

Evaluate the efficacy and safety of eculizumab in adults with AQP4-IgG+ NMOSD (NCT01892345).

### **Background**

Complement activation is a major component of CNS inflammation and astrocytic injury in patients with NMOSD. Eculizumab effectively inhibits C5 terminal complement activation.

## Design/methods

PREVENT was a global phase 3, randomized, double-blind, study designed to end at 24 on trial relapses (adjudicated by blinded, independent, expert panel). Patients (aged  $\geq 18$  years) were randomized 2 : 1 to eculizumab (1200 mg every 2 weeks maintenance) or placebo. Stable-dose supportive immunosuppressive therapy (IST) was permitted. Patients receiving rituximab in the prior 3 months were excluded.

## Results

Overall, 213 patients were screened, 143 randomized (90.9% women, median age 45.0 years) and 124 completed the study (eculizumab 80/96 [83.3%], placebo 44/47 [93.6%]). Between-group baseline annualized relapse rates (ARRs) (eculizumab mean=1.94 [SD=0.896], placebo 2.07 [1.037]) and supportive IST use (eculizumab, 78.1% of participants ; placebo, 72.3%) were similar. The study was stopped at 23 adjudicated on-trial relapses (eculizumab, n=3 ; placebo, n=20). Eculizumab had a significant effect on time to first adjudicated on-trial relapse (primary endpoint,  $p < 0.0001$ ), demonstrating a 94.2% reduction in relapse risk compared with placebo (HR, 0.058 [95% CI : 0.017-0.197]). At 48 weeks, 97.9% (95% CI : 91.8-99.5%) of eculizumab-treated participants were relapse-free compared with 63.2% (46.8-75.8%) for placebo. Adjudicated on-trial ARR (first secondary endpoint) was significantly lower with eculizumab (0.016 [95% CI : 0.005-0.050]) than placebo (0.350 [0.199-0.616]) (rate ratio, 0.045 [0.013-0.151],  $p < 0.0001$ ). For eculizumab and placebo groups, treatment exposure was 170.0 and 51.5 patient-years and treatment-emergent adverse event (TEAE) rates were 749.3 and 1160.9 per 100 patient-years, respectively. Most TEAEs were mild to moderate. One on-study death occurred in an eculizumab-treated patient (infectious pleural effusion). No meningococcal infections were reported.

## Conclusions

Eculizumab significantly reduced relapse risk in patients with AQP4-IgG+ NMOSD. The safety profile was similar to that in other indications.



### SS-3 AQP4 IgG: production, detection and destruction

Patrick Waters PhD



University of Oxford

The diagnosis of demyelinating disease has been simplified over the last 10 to 15 years with the discovery of antibodies to aquaporin-4 and myelin oligodendrocyte glycoprotein. These antibodies identify adults and children who do not have MS and their associated diseases are distinct. The treatment requirements and prognoses are different : patients with AQP4 antibodies most often require lifelong treatment and disability is attack related hence the importance of relapse prevention. Long-term disability in MOG+ patients is most frequently due to the onset attack, hence accurate, early detection of antibodies is important. In this talk I will discuss the different modalities developed for the detection of pathogenic antibodies, their strengths and caveats. I will describe the expanding onset phenotype associated with MOG antibodies and highlight treatment issues. I will present the available data on disease mechanism in NMO, which includes functional impairment of the water channel, internalisation of AQP4 arrays from the astrocyte cell surface and complement mediated astrocyte destruction. Finally, I will show some unexpected data on the b-cell lineages involved in AQP4 antibody production and their implications for future research and on-going treatment.

## CURRICULUM VITAE

Patrick Waters received a BSc in Biochemistry from University College Cork, Ireland and a PhD from the University of East London, UK. He has worked as a research scientist at the University of Oxford for 17 years developing diagnostic tests for antibodies associated with central nervous system diseases and animal models to demonstrate pathogenicity. He, and the University of Oxford, holds patents for the discovery of LGI1, CASPR2 and the GABA-A Receptor as targets in CNS autoimmunity. He is currently co-director of the Oxford Autoimmune Neurology Diagnostic Laboratory and has a research team investigating the B-cell receptor usage in CNS autoimmunity.



### OS2-1 Modulation of experimental autoimmune encephalomyelitis by *Mycobacterium avium* subsp. *paratuberculosis* or by BCG

Cossu Davide, Yokoyama Kazumasa, Hattori Nobutaka

Juntendo University

**Background** : Accumulating evidence supports a zoonotic potential of *Mycobacterium avium* subsp. *paratuberculosis* (MAP), the causative agent of Johne's disease in ruminants, in the pathogenesis of multiple sclerosis (MS), while BCG appears to protect from the disease. In this study we investigated the adjuvant and encephalitogenic effect of mycobacterial antigenic components on EAE, as well as the efficacy of oral administration of heat-killed MAP or BCG vaccination on EAE development.

**Methods** : groups of C57BL/6 mice were actively immunized with myelin oligodendrocyte glycoprotein (MOG)<sub>35-55</sub> peptide emulsified in incomplete Freund's adjuvant modified containing heat-killed MAP (MIFA). Moreover, groups of C57BL/6 mice were immunized with MAP through the oral route or by BCG intradermally 4 weeks before EAE induction.

**Results** : MOG-MIFA immunized mice showed an early disease onset and more severe clinical scores in comparison with MOG-CFA immunized mice (containing *Mycobacterium tuberculosis*). Orally MAP pre-treated mice displayed same symptoms of control mice, with an early onset and less severity, while pre-BCG-vaccinated mice did not develop symptoms of the disease following immunization.

FACS analysis showed that different subsets of Breg (CD19<sup>+</sup> CD5<sup>+</sup> CD1d<sup>hi</sup>) cells were higher in mice previously immunized with mycobacteria

**Conclusions** : we have shown for the first time a strong adjuvant effect of MAP in the development and progression of EAE, providing an alternative and reproducible method for understanding the mechanism responsible for the generation of autoimmune response of CNS. Mycobacteria are capable to modulate the priming and effector stages of EAE.

### OS2-2 Cognitive impairments and regional brain volume in multiple sclerosis and neuromyelitis optica spectrum disorder : a cross-sectional observational study

Ryouhei Komaki<sup>1</sup>, M.D., Tomoko Okamoto<sup>1</sup>, M.D., Ph.D., Yukio Kimura<sup>2</sup>, M.D., Ph.D., Manabu Araki<sup>1,3</sup>, M.D., Ph.D., Youwei Lin<sup>1,3</sup>, M.D., Wakiro Sato<sup>3</sup>, M.D., Ph.D., Noriko Sato<sup>2</sup>, M.D., Ph.D., Takashi Yamamura<sup>3</sup>, M.D., Ph.D., Yuji Takahashi<sup>1</sup>, M.D., Ph.D..

<sup>1</sup> Department of Neurology, National Center Hospital, National Center of Neurology and Psychiatry,

<sup>2</sup> Department of Radiology, National Center Hospital, National Center of Neurology and Psychiatry,

<sup>3</sup> Department of Immunology, National Institute of Neuroscience, National Center of Neurology and Psychiatry

#### Objective

To determine the specific brain regions that are responsible for cognition in multiple sclerosis (MS) and neuromyelitis optica spectrum disorder (NMOSD) patients.

#### Methods

We retrospectively analyzed 75 MS and 13 NMOSD patients who underwent assessments for cognition with the Wechsler Adult Intelligence Scale-III (WAIS-III). Regional brain volume was measured on T1-weighted brain MRI using the FreeSurfer software. Correlations between cognitive profiles and regional brain volume were analyzed.

#### Results

Mean age at the onset, disease duration, sex, and median Kurtzke Expanded Disability Status Scale (EDSS) did not differ between the MS and NMOSD patients. The score for processing speeds (PS) was significantly lower than those for other subscales of WAIS-III [verbal comprehension (VC);  $86.99 \pm 15.40$ , perceptual organization (PO);  $82.55 \pm 19.19$ , working memory (WM);  $83.26 \pm 18.66$ , PS;  $72.90 \pm 17.09$ ], especially in the MS patients. Multivariable linear regression revealed that the volumes of the subcortical gray matter structures, especially bilateral putamen, were negatively correlated with PO, WM, and PS; volumes of the right hippocampus and nucleus accumbens were negatively correlated with VC, PO, and WM. Additionally, the volume of the cingulate white matter was correlated with PS. The volumes of the medial temporal lobe, especially, right fusiform, parahippocampal, and bilateral entorhinal cortex, were correlated with VC.

#### Conclusion

Processing speeds were largely impaired in MS and NMOSD patients than in patients with other cognitive profiles. The striatum and cingulate were associated with processing speed. Medial temporal lobe gray matter was associated with verbal comprehension.

### OS2-3 Altered microbiota could affect distinct CNS immune gene expressions in the Theiler's virus model of MS

Fumitaka Sato, Ph.D., Seiichi Omura, Ph.D., Ah-Mee Park, Ph.D., Mitsugu Fujita, M.D., Ph.D., Sundar Khadka, M.S., Namie Sakiyama, Aoshi Katsuki, Yumina Nakamura, Kazuto Nishio, M.D., Ph.D., Ikuo Tsunoda, M.D., Ph.D.

Kindai University, Osaka, Japan

Multiple sclerosis (MS) is an inflammatory demyelinating disease in the central nervous system (CNS), which has been associated with an interaction between immune responses and microbes. The gut microbiota can affect systemic immune responses, contributing to pathology in remote organs including the CNS. Although dysbiosis has been reported in MS patients, it is unclear how the gut microbiota, the immune system, and the CNS communicate one another. We conducted a time course study using a viral model of MS, Theiler's murine encephalomyelitis virus (TMEV) infection, in which inflammatory demyelination is induced during the chronic phase, 1 month post infection (p.i.). We infected SJL/J mice with TMEV and harvested the CNS tissues and feces 4, 7, and 35 days p.i. We examined the CNS transcriptome and the fecal microbiome by RNA sequencing and 16S rRNA sequencing, respectively. Comparisons of the bacterial diversity among the groups demonstrated that the diversity of microbiota during the chronic phase, 35 days p.i., was higher than those of the other time points as well as uninfected controls. Pattern matching between the CNS transcriptome and fecal microbiome showed that the increased *Coprococcus* and *Marvinbryantia* genera 35 days p.i. correlated with upregulations of distinct immunoglobulin genes, *Ighd2-8* and *Igkv3-12*, respectively. Using an unsupervised approach, principal component analysis, we found that overall differences of microbiome distinguished samples between the three time points and that the increased *S24-7* family and decreased *Anaeroplasm* genus correlated with principal component 2 values reflecting CNS inflammation. In TMEV infection, altered abundance of distinct bacterial genera could influence expressions of different immune genes positively or negatively, leading to CNS inflammation.

### OS2-4 CSF-derived circulating cell-free DNA as a diagnostic biomarker : learning from a patient with multiphasic tumefactive lesions of the CNS during three years

Aiko Isami<sup>1</sup>, Izumi Kawachi<sup>1</sup>, Etsuji Saji<sup>1</sup>, Jun Watanabe<sup>2</sup>, Fumihiko Yanagimura<sup>1</sup>, Takahiro Wakasugi<sup>1</sup>,  
Manabu Natsumeda<sup>2</sup>, Osamu Onodera<sup>1</sup>

<sup>1</sup> Department of Neurology, Brain Research Institute, Niigata University

<sup>2</sup> Department of Neurosurgery, Brain Research Institute, Niigata University

A 32-year-old man presented with headache and uveitis in August 20XX. Brain MRI demonstrated a tumefactive lesion with gadolinium enhancement (GdE) in the right frontal lobe. Intravenous methylprednisolone resulted in disappearance of the lesion. One year later, he noted a transient hypesthesia in the right mouth corner, and MRI showed two tumefactive lesions with GdE in the left parietal lobe. The lesions again diminished by intravenous methylprednisolone. Serum testing via cell-based assays yield negative results for aquaporin-4 antibodies and myelin oligodendrocyte glycoprotein antibodies. CSF analysis revealed an elevated IgG index. He was suspected of having tumefactive multiple sclerosis and was treated with oral steroids. However, three years later, MRI scans revealed new asymptomatic lesions with GdE. The lesions were gradually expanded even with several courses of steroid pulse therapy. Repeated CSF analysis showed slightly high concentration of inflammatory cytokines/chemokines including interleukin (IL)-10, IL-8/CXCL8 and IL-6, but no oligoclonal bands and no malignant cells. Genomic assessment of CSF-derived circulating cell-free DNA identified somatic mutation in *MYD88*. Brain biopsy showed the diffuse large B cell lymphoma (DLBCL). He was thus diagnosed as having DLBCL-type primary CNS lymphoma (PCNSL) with three years of disease course, although lesions diminished by steroid treatments during initial two years. The occupied lesions diminished after chemotherapy.

The genomic profiles of DLBCL-type PCNSL are characterized by high frequency of nonsynonymous somatic mutations in *MYD88*, *PIMI* and *BTG2*. *MYD88* are involved in the NF- $\kappa$ B signaling pathway that promotes cell division and inflammation. Recent progresses suggest that *MYD88* mutated pre-lymphoma cells originate outside of the CNS, additional genetic hits confer adaptation to the CNS environment, and they then develop into lymphoma in the CNS. Genomic assessment of CSF-derived circulating cell-free tumor DNA should be of significant diagnostic value to patients with multiphasic tumefactive lesions of the CNS even during several years.

## SS-4 Learning MS immunopathogenesis via therapeutic interventions : novel insights



Heinz Wiendl, MD, PhD

Professor at Muenster University

Director at Department of Neurology with Institute of Translational Neurology at Muenster University

Honorary Professor at Sydney University

### Short summary of the work I will present :

The immune system plays a critical role in a variety of neuropsychiatric diseases and represents an interesting target for treatment strategies. The talk will provide examples from the 3 key research areas in my group, 1) immune regulation and protective immunity, 2) mechanisms of inflammatory neurodegeneration, 3) prognostic and therapeutic markers, especially focusing on the aspect, how deep immune phenotyping studies and the use of a "reverse and refined translation approach" can aid to the understanding of neuroimmunological mechanisms in CNS inflammatory disorders, specifically novel pathomechanistic insights into MS.

### Literature :

Kappos, Wiendl et al, NEJM 2015

Gross et al., PNAS 2016

Breuer et al, Ann Neurol 2014

Mykicki et al., Science Trans Med 2016

Schneider-Hohendorf et al., JEM 2014

Gerwien et al., L. Science Trans Med 2016

Klotz, PNAS 2016

Goebel, PNAS 2018

Klotz, Science Trans Med 2019

## CURRICULUM VITAE

### **Short bio :**

Prof. Wiendl studied medicine in Germany, Switzerland and USA, graduating in 1996. After working as a research fellow at the Institute of Neuroanatomy, Nuremberg, the Max Planck Institute for Neurobiology and the Department of Neurology Tuebingen, he became head of a clinical research group for MS in Wuerzburg in 2005 and acted as a vice-chair of the Department of Neurology. In 2010 he was recruited to Muenster University as director of the Department of Neurology – Inflammatory Disorders of the Nervous System and Neurooncology. Since 2013 he is head of the Department of Neurology Muenster, since 2017 head of the Department of Neurology with Institute of Translational Neurology. His research focusses on inflammatory neurodegeneration, immune regulation and protection, as well as monitoring MS and its therapy.

His achievements have been recognized by both Sobek awards of the German Society for MS(DMSG) (2004 ; 2015). In 2017 he was appointed Honorary Professor at Sydney Medical School.

He is speaker of a transregional centre grant on MS(CRC TR128), cospeaker of the German competence network of MS(KKNMS), PI of the Cluster of excellence CIM(cells in motion)and involved in several multicentric research networks.

## SS-5 Cognitive impairment in multiple sclerosis and its measurement in daily clinical practice



Iris-Katharina Penner

Heinrich Heine University Düsseldorf, Department of Neurology & Cogito Center for Applied  
Neurocognition and Neuropsychological Research, Düsseldorf, Germany

Cognitive impairment belongs to the key symptoms in Multiple Sclerosis (MS) affecting 40-50% of patients. It has a tremendous effect on quality of life and vocational status but is not necessarily related to EDSS or disease duration. The most typically affected cognitive domains are information processing, short-term memory/learning and mental flexibility. Since these cognitive aspects are highly relevant for daily functioning reliable and early assessment is mandatory. Several studies have tried to find a direct structural or functional correlate being able to explain the occurrence of cognitive decline. The overall conclusion is that not the simple number of lesions is responsible but their location. In case that lesions are located in brain regions highly relevant for cognitive processing (e.g. prefrontal cortex, thalamus, parietal cortex) the probability of cognitive decline increases. Since human cognition depends on a highly interconnected neuronal network, cognitive decline can be understood as result of a network collapse. Assessment of cognitive problems on a regular basis is important to monitor patients over time and to support treatment decisions. The Brief International Cognitive Assessment for MS (BICAMS) has been introduced as international standard to offer a time economic option suitable for needs in standard clinical care.

## CURRICULUM VITAE

Prof. Dr. Iris-Katharina Penner

### Competency Profile

Cognitive Neuroscientist and neuropsychologist with 20 years of experience in neurocognitive research with a strong focus on neurodegenerative and neuroinflammatory diseases of the CNS

- Nationally and internationally renowned expert and KOL in the field of human cognition
- Highly experienced collaboration partner for pharmaceutical companies
- Results-oriented, entrepreneurial scientist who thrives on going where nobody went before
- Creative developer of patient reported outcomes and assessment tools applied in clinical trials and standard clinical care
- Trusted and highly respected thought leader, strategic thinker and advisor with an outstanding ability to motivate people and to obtain excellence in performance

### Current Role

Since 10/2016 Professor at the Neurology Department, University Hospital Düsseldorf, Germany

Areas of responsibility :

- Board member of the Multiple Sclerosis Unit (Prof. Dr. H.P. Hartung)
- Neuropsychological expert for clinical examinations of patients with various CNS diseases
- Leader of translational research projects
- Teaching of medical students in cognitive neuroscience

Since 11/2014 Founder and Director at COGITO Center for Applied Neurocognition and Neuropsychological Research, Düsseldorf, Germany

As I believe in empowering (cognitively impaired) patients, I founded the COGITO Center in November 2014 in Düsseldorf, Germany. By developing and applying disease sensitive assessment and training tools, we help patients to understand their cognitive problems in more depth and further develop their insights into treatment approaches beyond medication to help protect the brain from inflammation and neurodegeneration. The focus areas of the COGITO Centre are

- Neurocognitive Research (including methods such as MRI, OCT, PET, Biobanking)
- Neuropsychological assessment (application and development)
- Clinical trials and IITs
- Neuropsychological therapy (application and development)
- Expert opinions



### **P-1 Programmed death 1 (PD-1) inhibitor-associated myasthenia gravis with necrotizing myopathy and myocarditis: case report and literature review**

Ryotaro Ikeguchi, Hayato So, Masaki Kobayashi, Miki Suzuki, Yuko Shimizu, and Kazuo Kitagawa

Department of Neurology, Tokyo Women's Medical University, Tokyo

#### **Background**

Programmed cell death protein 1 (PD-1) inhibitors are effective for treating unresectable malignancies. However, PD-1 inhibitors can have undesired neurological side effects. Here, we present a patient with PD-1 inhibitor-associated severe myasthenia gravis (pMG) with necrotizing myopathy and myocarditis who had history of positivity of AChR Ab.

#### **Case presentation**

A 55-year-old woman with metastatic melanoma presented with a myalgia and an increased CK level after the second infusion of nivolumab. Her medical history included a thymectomy for thymoma, 6 years prior, during which she tested seropositive for AChR Ab. She then developed ptosis, bulbar symptoms, and limb weakness. She also presented with wide QRS complex tachycardia. Echocardiography revealed dyssynchrony of the left ventricle. Single-fiber electromyography revealed evidence of neuromuscular junction dysfunction. Biopsy of the quadriceps muscle demonstrated abundant necrotic fibers and scarce lymphocytic infiltration. The diagnosis of pMG complicated by necrotizing myopathy and myocarditis was confirmed. Despite administration of intravenous immunoglobulin (IVIg), she progressed to myasthenic crisis and required mechanical ventilation. Following intensive immunotherapies, her symptoms improved gradually. At day 180, ventilatory support was weaned off.

#### **Literature review**

To date, there have been 44 reported cases of pMG and only a few reports of this condition concomitant with myocarditis. Eight had a history of MG, 3 were seropositive for AChR Ab without MG symptoms, and none with thymoma before PD-1 inhibitor initiation. Most patients (38/42, 90%) developed pMG before the fourth infusion of PD-1 inhibitor (mean 2.2 infusion). Mechanical ventilation was required in 16 out of 43 cases (37%). Moreover, 16 out of 42 cases (38%) died.

#### **Conclusions**

History of MG and/or AChR Ab positivity may be potential risk factors of MG onset in patients undergoing treatment with PD-1 inhibitors. Therefore, it may be beneficial to screen patients for AChR Ab and a history of MG prior to initiating PD-1 inhibitor.

### **P-2 IMMUNOSUPPRESSIVE ROLE OF SULFATIDE IN THE PATHOGENESIS OF MULTIPLE SCLEROSIS**

Mio Hamatani<sup>1</sup>, Shinji Ashida<sup>2</sup>, Kimitoshi Kimura<sup>1</sup>, Chihiro Fujii<sup>2</sup>, Hirofumi Ochi<sup>3</sup>, Ryosuke Takahashi<sup>1</sup>, Takayuki Kondo<sup>4</sup>

<sup>1</sup> Department of Neurology, Kyoto University Graduate School of Medicine, Kyoto, Japan.

<sup>2</sup> Department of Neurology, Graduate School of Medical Science, Kyoto Prefectural University of Medicine, Kyoto, Japan.

<sup>3</sup> Department of Neurology and Geriatric Medicine, Ehime University Graduate School of Medicine, Toon, Japan.

<sup>4</sup> Department of Neurology, Kansai Medical University Medical Centre, Osaka, Japan.

#### **OBJECTIVE**

Autoimmunity to myelin components is crucial in the pathogenesis of multiple sclerosis (MS). However, accumulating knowledge is skewed to regarding myelin proteins and the association of other myelin components with MS has not been much studied. Sulfatide is one of myelin-glycolipids, hence is assumed to be released at the site of demyelination. Indeed, sulfatide was elevated in serum and cerebrospinal fluid of patients with MS. Moreover, sulfatide was reported to ameliorate experimental autoimmune encephalomyelitis. Hence, involvement of sulfatide in MS pathogenesis is of much interest. In this study we aim to unravel immunological effects of sulfatide and its mechanism.

#### **METHODS**

Peripheral blood mononuclear cells (PBMCs) were obtained from healthy volunteers. For flow cytometric analysis of T cell proliferation, PBMCs were stained with cytoplasmic dye and cultured with anti-CD3 antibody alone or with anti-CD28 antibodies in presence or absence of sulfatide. Proliferation in response to human recombinant interleukin 2 (IL-2) was also analyzed. Expression of cell-surface and intracellular signalling molecules was also analyzed with FCM. Cytokine quantity in culture medium was measured by cytometric bead-array system with FCM.

#### **RESULTS**

Sulfatide suppressed T cell proliferation in response to both anti-CD3/CD28 antibodies and IL-2. Co-incubation of IL-2 with sulfatide resulted in decreasing FCM-detectable IL-2 concentration and in attenuating its potential in phosphorylation of signal transducer and activator of transcription 5 (STAT5) in T cells. These results are interpreted that sulfatide directly abrogates the interaction of IL-2 with its receptor. Sulfatide also downregulated expression levels of CD4 and CD28 on T cells and of HLA-DR, CD80, CD86 and CD40 on monocytes. Dampening interaction of T cells and antigen presenting cells may be another inhibitory pathway of T cell proliferation mediated by sulfatide.

#### **CONCLUSION**

Sulfatide suppresses T cell activation in several fashions and may play beneficial roles in the pathogenesis of MS.

### **P-3 An undiagnosed case of childhood-onset recurrent demyelinating or inflammatory brainstem lesions**

Hideaki Mashimo<sup>1</sup>, Satoko Kumada<sup>1</sup>, Yoko Warabi<sup>2</sup>

<sup>1</sup> Department of Neuropediatrics, Tokyo Metropolitan Neurological Hospital

<sup>2</sup> Department of Neurology, Tokyo Metropolitan Neurological Hospital

We report a 21-year-old male with recurrent demyelinating or inflammatory brainstem lesions. His developmental milestones were normal and he had no family history of disease except for his mother's recurrent hemifacial palsy. At age 8 years, he developed vomiting, nystagmus, oculomotor disturbances, and ataxia. Magnetic resonance imaging (MRI) identified lesions in the right middle cerebellar peduncle, which showed high intensities on T2-weighted imagery and were enhanced by gadolinium (Gd). The patient's symptoms and MRI lesions initially improved with intravenous methylprednisolone pulse therapy, but afterwards, similar episodes have repeatedly recurred for 12 years. Although he shows multifocal brainstem lesions, he has not developed lesions in the cerebrum, optic tracts, or spinal cord. Intermittent intravenous immunoglobulin therapies (IVIG) were effective for preventing relapses. In contrast, interferon- $\beta$  aggravated the relapses and caused leukopenia. Examination of complete blood count, blood chemistry (including ACE, and serum autoantibodies, including anti-AQP4, anti-MOG, anti-GQ1b, and anti-NMDA receptor antibodies) revealed no abnormalities. CSF analyses revealed normal cell count, protein, myelin basic protein, ACE, and IL-6 levels. The CSF oligoclonal band was negative, as was a polymerase chain reaction study for herpes simplex virus. HLA-B51, Cw1, and B54 were negative. Ophthalmological examinations revealed no abnormalities, and chest XP revealed no hilar lymphadenopathy. We concluded that he must suffer from an undetermined neuroimmunological disease localized to the brainstem. His clinical manifestations and neuroradiological and laboratory findings are inconsistent with multiple sclerosis, neuromyelitis optica, Bickerstaff brainstem encephalitis, neuro-Bechet disease, neuro-Sweet disease, neurosarcoidosis, brainstem encephalitis with herpes simplex virus, and chronic lymphocytic inflammation with pontine perivascular enhancement responsive to steroids (CLIPPERS).

## Poster Session

### **P-4 Serum Sema4A levels correlate with distinct clinical phenotype in patients with NMOsd**

Shohei Beppu<sup>1</sup>, Tatsusada Okuno<sup>1</sup>, Makoto Kinoshita<sup>1</sup>, Toru Koda<sup>1</sup>, Teruyuki Ishikura<sup>1</sup>, Hisashi Murata<sup>1</sup>, Yuji Nakatsuji<sup>2</sup>, Hideki Mochizuki<sup>1</sup>

<sup>1</sup> Department of Neurology, Osaka University Graduate School of Medicine, Osaka, Japan.

<sup>2</sup> Department of Neurology, Toyama University, Toyama, Japan.

#### **Background**

Sema4A is one of the membrane-type class IV semaphorins, which play important roles in the immune system. We previously established ELISA system to measure Sema4A and reported that serum Sema4A level is significantly higher in multiple sclerosis (MS) than that in other neurological diseases. Patients with high Sema4A levels show Th17 skewing, which indicates the possible correlation between Sema4A and neuromyelitis optica spectrum disorder (NMOsd). Thus, in this study we aimed to clarify the clinical characteristics of patients with NMOsd based upon the varying serum Sema4A levels.

#### **Methods**

We measured serum Sema4A level in 47 NMOsd and 129 MS patients using ELISA system. All NMOsd patients were positive for serum anti-aquaporin 4 antibody (AQP4ab). Blood samples were obtained from NMO patients during the initial onset.

#### **Results**

The titer of serum Sema4A in NMOsd was  $5675 \pm 9258$  U/ml, whereas that in MS was  $3145 \pm 5526$  U/ml. 16 NMOsd patients showed serum Sema4A levels higher than 2500 U/ml, and those with high serum Sema4A levels showed younger age at onset (high  $39 \pm 11$  vs low  $51 \pm 10$ ). Furthermore, NMOsd with high Sema4A group showed higher prevalence of myelitis. Serological study also revealed high positivity for anti-SS-A and SS-B Abs in those patients. EDSS score was significantly lower among the high Sema4A group.

#### **Conclusion**

In this series of analysis, serum Sema4A level in NMOsd is as high as that in MS and the titer levels affect the onset and the severity in NMOsd. Further investigations are required to clarify the significance of Sema4A in the pathogenesis of NMOsd.

### **P-5 A case of bilateral hypothalamic lesions with anti-NAE autoantibodies.**

Yuji Tomizawa, Yuka Hosaka, Yoshiaki Furukawa

Department of Neurology, Juntendo Tokyo Koto Geriatric Medical Center

Bilateral hypothalamic lesions are often observed in patients with neuromyelitis optica spectrum disorder. Bilateral hypothalamic lesions can occur symptomatic narcolepsy with disruption of orexin neurons. NH<sub>2</sub>-terminal of  $\alpha$ -enolase (NAE) antibodies was reported to be specific to Hashimoto's encephalopathy. Here, we report a case of a 78-year-old woman presented with bilateral hypothalamic lesions in MRI and developed symptomatic narcolepsy. Anti-aquaporin 4 antibodies were negative in both serum and cerebrospinal fluid. Anti-NAE antibodies were detected in the serum. Orexin concentration in the cerebrospinal fluid had a low value of 65 pg/mL (<110 pg/mL). The patient was diagnosed with symptomatic narcolepsy by the immunological physiology. Corticosteroid treatment was effective. The symptoms and MRI findings improved, and the patient was discharged 45 days after admission. No specific findings other than anti-NAE antibodies were found in this patient. No previous reports exhibited hypothalamic lesion in the case of Hashimoto's encephalopathy. Therefore, whether this case was a spectrum of Hashimoto's encephalopathy or not remains to be elucidated.

### **P-6 Long-term follow-up of a patient with anti-MOG antibody seropositive treated by steroid over 10 years.**

Takeshi Araki<sup>1</sup>, Norio Chihara<sup>1</sup>, Kento Matoba<sup>1</sup>, Hisatsugu Tachibana<sup>1</sup>, Yoshihiro Kuga<sup>2</sup>, Takanori Hirose<sup>3</sup>, Yoshihisa Otsuka<sup>1</sup>, Takehiro Ueda<sup>1</sup>, Kenji Sekiguchi<sup>1</sup>, Riki Matsumoto<sup>1</sup>.

<sup>1</sup> Division of Neurology, Kobe University Graduate School of Medicine

<sup>2</sup> Department of Neurosurgery, Ohnishi Neurological Center

<sup>3</sup> Division of Diagnostic Pathology, Hyogo Cancer Center

We report a patient seropositive for antibody against myelinoligodendrocyte glycoprotein (MOG) who showed a partial steroid-responsiveness with multiple relapses over a long-period of time. A 27-year-old man was referred to our hospital for the diagnosis of a 12-year history of relapsing-remitting neurological symptoms. He was admitted to a local hospital with the complains of 2-year memory disturbance, headache and agraphia 10 year ago and brain MRI revealed a ring-enhancing lesion in the left parietal periventricular white matter. A brain biopsy was performed and revealed an inflammatory lesion. Thus, steroid treatments were administrated both intravenously and perorally that showed a preferable response. Thereafter, he experienced 13 times disease relapses such as diplopia, right hemiplegia and general malaise over 10 years. The dose of oral prednisolone was 10-15 mg/day. On admission to our hospital, neurological examination revealed recent memory disturbance, severely impaired gag reflex, homonymous quadrantanopsia, right dominant bilateral pyramidal tract signs, cerebellar ataxia, and hypoesthesia in the right leg (EDSS score was 6.0). Symbol Digit Modalities Test score was 22. Laboratory findings demonstrated leukocytosis and renal dysfunction. A cerebrospinal fluid study showed two Oligoclonal bands. Brain MRI revealed FLAIR hyperintensity lesions with ring-enhancement in the left parietal and right inferior temporal white matter as well as lesions without gadolinium-enhancement in the periventricular white matter, splenium of the corpus callosum and brainstem. Cerebellar atrophy was also observed. Spinal-cord MRI showed hyperintensity lesions in the T2-weighted image. The pathological specimen biopsied 10-year ago was reexamined and exhibited demyelinating findings. Serum anti-MOG antibody was positive and anti-aquaporin-4 antibody was negative. Previous studies reported anti-MOG antibody associated demyelination was responsive to low-dose oral steroids. This patient showed steroid-responsiveness but frequent relapses like a natural history of multiple sclerosis, and developed cognitive impairments and severe physical disabilities that should have required more intensive immune-suppressive treatment.

## Poster Session

### **P-7 An elevated GFAP level revealing MRI-undetected NMO relapse with truncal pruritus and paresthesia.**

Ayako Koguchi, Ryosuke Yusa, Mizuho Kawai, Akihiko Mitsutake, Tatsushi Toda, Kaori Sakuishi

The University of Tokyo, Department of Neurology

Neuromyelitis optica spectrum disorders (NMOSD) are autoimmune inflammatory diseases of the central nervous system characterized by dissemination in time and space, demyelination and axonal damage mainly at optic nerves and spinal cord. The presence of serum NMO-immunoglobulin G (IgG) antibody that binds to aquaporin-4 (AQP4) at the foot processes of astrocyte distinguishes NMO from other NMOSD. In addition to neurological symptom and MRI imaging, pleocytosis and high ratio of IgG in serum and cerebrospinal fluid (CSF) delineate relapses. Past studies have shown IL-17, IL-6, BAFF (B cell activating factor belonging to the tumor necrosis factor family), GFAP (glial fibrillary acidic protein) in CSF (GFAP-CSF) are useful biomarkers for NMO. In fact, GFAP-CSF has been lately considered as one of the quantitative biomarkers which may reflect the degree of severity in NMO. In this study, we suspected a relapse in an anti-AQP4 antibody positive 27-year-old woman with a sudden onset of itching paresthesia and burning sensation in her rt flank at Th10-12 dermatome level. She had been on oral PSL treatment with prior history of NMO attacks. Lumbar puncture revealed 87 cells /mm<sup>3</sup> in CSF, however, no lesions were observed by brain/spinal cord MRI. With possibility of NMO relapse, she received three courses of intravenous methylprednisolone pulse therapy (IVMP) to which both her symptoms and CSF pleocytosis responded. To investigate on the etiology of this event, we measured GFAP-CSF. The level was high before IVMP and had decreased post treatment. In contrast, repeated MRI scans did not detect any consistent lesions. Our case confirms that paresthesia with itchiness (neuropathic pruritus) can be a characteristic sign of a spinal cord damage caused by active NMO inflammation. Our finding also opens up a potential of applying GFAP-CSF as a sensitive qualitative biomarker for underdiagnosed NMO myelitis.

### P-8 Lhermitte's sign due to thoracic spinal cord lesion in neuromyelitis optica

Ryuhei Harada<sup>1</sup>, Yoko Warabi<sup>1</sup>, Utako Nagaoka<sup>1</sup>, Eiji Isozaki<sup>1</sup>

<sup>1</sup>Department of Neurology, Tokyo Metropolitan Neurological Hospital, Tokyo, Japan

A 78-year-old woman who was diagnosed with neuromyelitis optica (NMO) being seropositive for anti-aquaporin-4 antibody, described a throbbing pain in her back and chest, which spread from her knees to the toes in about two weeks. Furthermore, she had begun to experience an electric shock-like sensation radiating from her back to the toes when her neck was flexed forward. She was admitted to our hospital based on the suspicion of an NMO relapse. Although a magnetic resonance imaging (MRI) of the cervical spine did not reveal any abnormalities, MRI of the thoracic spine showed T2-weighted intramedullary signal hyperintensity from the second to the third thoracic level with gadolinium contrast enhancement. She was treated with 2 courses of high-dose intravenous methylprednisolone, and thereafter she was continued on 5 mg of oral prednisolone and 75 mg of oral azathioprine. A day after the second course of methylprednisolone, thoracic MRI revealed the disappearance of the contrast-enhancement. Although numbness in the trunk and the lower extremities was relieved, an electric shock-like sensation running from the back to the toes during the neck flexion continued for about three months. Lhermitte's sign was originally described in 1924 as a symptom in which a transient electric-shock like sensation travels down the trunk to the lower limbs when the neck is flexed. Usually, Lhermitte's sign was known as diagnostic for cervical lesion in multiple sclerosis (MS). Few reports of MS causing Lhermitte's phenomenon due to lesions except for those of the cervical cord are known. In few cases, including metastatic tumors or spinal diseases, Lhermitte's phenomena due to thoracic cord lesions have been reported. Here we have described an NMO case causing Lhermitte's sign due to thoracic cord lesion. Therefore, careful interpretation of this classical neurological sign is required from a locational and etiological perspective.



### **P-9 A case of anti-MOG antibody positive neurological disease, mimicking neuromyelitis optica spectrum disorders – comparison of clinical feature between AQP4 and MOG antibody positive cases –**

Satoru Oji, Tetsuo Yamaga, Satoru Tanaka, Baku Hashimoto, Shoko Izaki, Masaomi Yamamoto, Masato Suzuki, Hikoaki Fukaura and Kyoichi Nomura

Department of Neurology, Saitama Medical Center, Saitama Medical University

A 34-years-old Japanese male presented with visual loss, muscle weakness of lower limbs, and urinary disturbance. Neurological examination showed the optic neuritis and transverse myelitis. The critical flicker fusion frequency was decreased in his bilateral eyes. The MRI showed mild swelling of optic nerves and longitudinally extensive spinal cord lesion, ranged C2-conus. The cerebrospinal fluid (CSF) test revealed elevated cell counts ( $181/\text{mm}^3$ ), total protein ( $221\text{mg/dL}$ ), myelin basic protein ( $18,300\text{ pg/mL}$ ), and quotient of CSF/serum albumin and IgG (QALB 40, QIgG 28). Serum anti-aquaporin 4 antibody was negative. His temporary diagnosis was seronegative neuromyelitis optica spectrum disorders (NMOSD). He was treated with intravenous methylprednisolone  $1,000\text{mg/day}$ ; 5 consecutive days (IVMP) and 3 times of immunoadsorption plasmapheresis (IAPP). His visual function showed moderate improvement, but there was no effect on myelitis. Then, he was treated with additional course of IVMP and IAPP, respectively. During his hospitalization, serum anti-myelin oligodendrocyte glycoprotein (MOG) antibody was detected, and finally, he was diagnosed as MOG-positive neurological disease (MOG-ND). The serum titer of MOG antibody indicated remarkably high values  $>4,096$ . His visual function recovered completely and myelitis showed mild improvement, and he transferred for the rehabilitation at the 50 hospital days. Previous reports described various clinical manifestations in patients with MOG-ND, such as optic neuritis, myelitis, cortical encephalitis, acute disseminated encephalomyelitis and NMOSD. Our case was MOG-ND which mimicked clinical manifestation of NMOSD. The frequency of MOG antibody in cases who diagnosed as seronegative NMOSD was reported as about 40 %. Our case highlighted the importance of MOG-IgG detection in patients who diagnosed as seronegative NMOSD.

### **P-10 A 70-year old female case of possible clinically isolated syndrome (CIS) successfully treated with corticosteroid and plasma pheresis**

Asako Tagawa, Takashi Koide

Department of Neurology, Hiratsuka City Hospital

Clinically isolated syndrome (CIS) is the first episode of multiple sclerosis (MS), and the patients who experienced CIS may or may not develop MS. MS predominantly affects young adults between about 20 and 40 years of age. We experienced a female case of 70 years old developed brainstem encephalitis successfully treated with corticosteroid pulse treatment and plasma pheresis. This episode was considered to be due to the CIS.

A 70-year old woman was suffered from diplopia and unsteady gait for more than two weeks, and she consulted to our hospital. She presented restriction of left ocular movements and right MLF syndrome, and unsteady gait. Neither cerebellar nor sensory ataxia were observed. MRI examination revealed high signal intensity of pontine and midbrain tegmentum on FLAIR and T2 weighted images. Open ring enhancement lesion was observed on pontine tegmentum. CSF oligoclonal band was positive, and serum anti-MOG antibody and anti-AQP4 antibodies were negative. Two courses of corticosteroid pulse treatment relieved her ocular symptoms. However, she newly developed the left MLF syndrome and relapsing inflammatory lesions from pons to midbrain was observed on MRI examination. After the three times of simple plasma pheresis treatment, her neurological symptoms disappeared, and no relapse of inflammation has been observed for more than 8 months after the first attack.

Very late onset MS occurring over 60-year old is rare, and represents about only 0.27 ~ 1.33 % of total MS population. However, in late onset MS, higher frequency of brainstem or spinal involvements as an initial attack, more rapid progress of EDSS, and shorter period until the second attack are reported in comparison with younger MS. We are continuing the careful observation of her clinical course.

### **P-11 Anti-myelin oligodendrocyte glycoprotein antibody-positive neuromyelitis optica spectrum disorder manifested by switching to dimethyl fumarate**

Keita Takahashi, Ryoko Fukai, Haruko Nakamura, Hiroyasu Komiya, Atsuko Katsumoto, Hiroshi Doi, Hideyuki Takeuchi, Fumiaki Tanaka

Department of Neurology and Stroke Medicine, Yokohama City University Graduate School of Medicine, Yokohama, Japan

Autoantibody against myelin oligodendrocyte glycoprotein (MOG) is often detected in anti-aquaporin 4 (AQP4) antibody-negative neuromyelitis optica spectrum disorder (NMOSD), and anti-MOG antibody-positive NMOSD shows broader spectrum of clinical features than anti-AQP4-positive NMOSD. Here we report three anti-MOG antibody-positive NMOSD cases manifested by switching to dimethyl fumarate. All patients showed transverse myelitis with short spinal cord lesions, and two patients also developed optic neuritis. However, all patients showed seronegativity of anti-AQP4 and anti-MOG antibodies by the cell-based assay. Therefore, they were first treated as multiple sclerosis. Methylprednisolone pulse therapy dramatically improved their symptoms, then, two patients were treated with fingolimod for 1–2.5 years without any exacerbation, but they developed severe relapses 3–11 months after drug switching to dimethyl fumarate. One patient was directly treated with dimethyl fumarate after methylprednisolone pulse therapy and also developed severe relapse within 2–3 months. The second cell-based assay finally revealed that all patients were anti-MOG antibody-positive NMOSD. Our report suggests that fingolimod, but not dimethyl fumarate, may be effective against anti-MOG antibody-positive NMOSD.

### **P-12 Identification of therapeutic target of Multiple Sclerosis through MALDI-Imaging Mass Spectrometry (IMS) for Experimental Autoimmune Encephalomyelitis (EAE) mouse spinal cords and brains**

Nami Tanaka<sup>1</sup>, Hiroki Yamashita<sup>1</sup>, Takashi Nirasawa<sup>2</sup>, Ryo Kajita<sup>2</sup>, Katsutoshi Taguchi<sup>3</sup>, Masaki Tanaka<sup>3</sup>, Takayuki Kondo<sup>4</sup>, Yudai Tsuji<sup>1</sup>, Nobuto Kakuda<sup>1</sup>, Masaya Ikegawa<sup>1</sup>

Doshisha University<sup>1</sup>, Bruker Japan K.K.<sup>2</sup>, Department of Anatomy and Neurobiology, Graduate School of Medical Science, Kyoto Prefectural University of Medicine<sup>3</sup>, Kansai Medical University Medical Center<sup>4</sup>

Experimental autoimmune encephalomyelitis (EAE) is a complex condition in which a variety of pathological mechanisms leads to an approximation of the key pathological features of Multiple Sclerosis (MS). In this study, we applied matrix-assisted laser desorption/ionization (MALDI) mass imaging mass spectrometry (IMS) for analyzing EAE mice at proteome level. We have prepared brains, spinal cords as well as whole animal body from defined clinical stages of EAE mice. Mass spectra were measured using the Ultraflex extreme and Rapiflex tissue typer with a spatial resolution of 50 to 70  $\mu$ m. For Protein ID experiments, trypsin was sprayed with TM-sprayer and peptide extraction from digested tissue samples was performed for LC-TIMS MS/MS analysis. As a result, we have succeeded in obtaining comprehensive protein mapping from brains and spinal cords of the EAE mice during the disease progression. Using multivariate analysis, a defined proteomic profile among early to acute phase EAE mouse brains were extracted. By single peak analysis, we found a few protein markers that co-localized with immune cell infiltrations in cerebellum, hippocampus as well as spinal cords at the pre-symptomatic to symptomatic phase of EAE. Among those candidate proteins, S100 proteins were nominated as the most useful biomarker proteins and were subsequently validated with immunohistochemistry (IHC). To functionally challenge this hypothesis, we are trying to block S100 protein signaling with a small molecule compound before and after the onset of EAE symptoms in the original EAE model. With current proteomic workflow on EAE, we have identified a novel therapeutic target of MS which must be further tested for the clinical implementation.

### **P-13 Exosomal microRNA profiles from cerebrospinal fluid in neuromyelitis optica spectrum disorders**

Ryohei Ohtani<sup>1,2</sup>

Masahiro Mori<sup>2</sup>, Akiyuki Uzawa<sup>2</sup>, Tomohiko Uchida<sup>2</sup>, Hiroki Masuda<sup>2</sup>, Jia Liu<sup>2</sup>, Reiji Aoki<sup>2</sup>, Satoshi Kuwabara<sup>2</sup>

<sup>1</sup> Department of Neurology, JR Tokyo general hospital

<sup>2</sup> Department of Neurology, Graduate School of Medicine, Chiba University

#### **Background**

Neuromyelitis optica spectrum disorders (NMOSD) is a central nervous system (CNS) inflammatory disease, characterised by severe optic neuritis and/or longitudinally extensive transverse myelitis. The antibody against aquaporin-4 (AQP4-Ab) is involved in the pathogenesis of NMOSD, whereas various seronegativity rates have been reported. MicroRNAs (miRNAs) can be transported by exosomes, which act as mediators of cell-to-cell communication and have the potential to be biomarkers. Therefore, we measured the profile of exosomal miRNA profiles from CSF in NMOSD.

#### **Methods**

CSF exosomes were obtained from patients with NMOSD and relapsing-remitting multiple sclerosis (RRMS), and controls. At first, we measured a total of 752 miRNAs using a quantitative reverse-transcription polymerase chain reaction analysis in patients with NMOSD and RRMS (each n = 3). Then, we validated the 12 most promising miRNAs in patients with NMOSD and RRMS, and controls (each n = 23).

#### **Results**

The screening of CSF exosomes from patients with NMOSD and RRMS detected 308 of 752 miRNAs. Of these, 202 miRNAs were detected in both the NMOSD and RRMS patients, 64 in only the NMOSD patients, and 42 in only the RRMS patients. Finally, we identified three miRNAs that had been up- or downregulated in NMOSD compared with RRMS and controls after validation. Especially, the expression level of miR-150-5p correlated positively with the CSF cell count and Expanded Disability Status Scale scores in NMOSD.

#### **Conclusion**

The exosomal microRNA profiles from CSF in NMOSD differed from those of RRMS patients and controls. We identified three miRNAs as candidate surrogate markers for NMOSD; one of these, miR-150-5p, may play a role based on CNS inflammation in disease severity in NMOSD.

## Delivering Life-Changing Therapies for Patients with Rare Diseases

アレクシオンは、効果的な治療の選択肢がほとんどない、重篤な希少疾患を抱える患者さんの生活を一変させるような治療薬を提供することを使命とした会社です。

生体内での重要な免疫機能の一つである補体の活性化を制御する薬剤を世界で初めて開発し、制御不能となった補体により引き起こされる発作性夜間ヘモグロビン尿症、非典型溶血性尿毒症症候群、および全身型重症筋無力症に苦しむ患者さんにお届けしています。

また、生命に不可欠な酵素が欠損する、低ホスファターゼ症、ライソゾーム酸性リパーゼ欠損症等の代謝性疾患に対する酵素補充療法を開発し、こうした疾患と闘う医療従事者や、QOLの低下に苦しむ患者さんとそのご家族の新たなチカラとなっています。

これからも希少疾患と闘う患者さんにご家族の笑顔のため、革新的な治療法を開発し、お届けしていきます。

ALXN-AD811-1904

**ALEXION**<sup>®</sup>  
アレクシオンファーマ合同会社  
<http://alexionpharma.jp>



未来人です。

少し先の未来から来ました。

あなたが想像する未来では、

車が空を飛んでいますか。

ロボットがお世話してくれていますか。

ところで医療の未来はどうか。

オーダーメイドの薬。

手のひらでわかる健康診断。


病気の事前予測。


バイオの力があれば、実現できるかも。

詳しくは未来で。

バイオでしか、行けない未来がある。

すべての革新は患者さんのために

 **中外製薬**

 ロシュグループ

創造で、想像を超える。



多発性硬化症治療剤  
**ジレニア® カプセル0.5mg**

薬価基準収載

劇薬 処方箋医薬品 注意—医師等の処方箋により使用すること

GILENYA®

フィンゴリモド塩酸塩カプセル

効能・効果、用法・用量、警告・禁忌を含む使用上の注意等については添付文書をご参照ください。

製造販売

(資料請求先)

**ノバルティス ファーマ株式会社**  
東京都港区虎ノ門1-23-1 〒105-6333

NOVARTIS DIRECT

0120-003-293

受付時間：月～金 9:00～17:30

(休祭日及び当社休日を除く)

www.novartis.co.jp

2016年9月作成



## Better Health, Brighter Future

タケダから、世界中の人々へ。より健やかで輝かしい明日を。

一人でも多くの人に、かけがえのない人生をより健やかに過ごしてほしい。タケダは、そんな想いのもと、1781年の創業以来、革新的な医薬品の創出を通じて社会とともに歩み続けてきました。

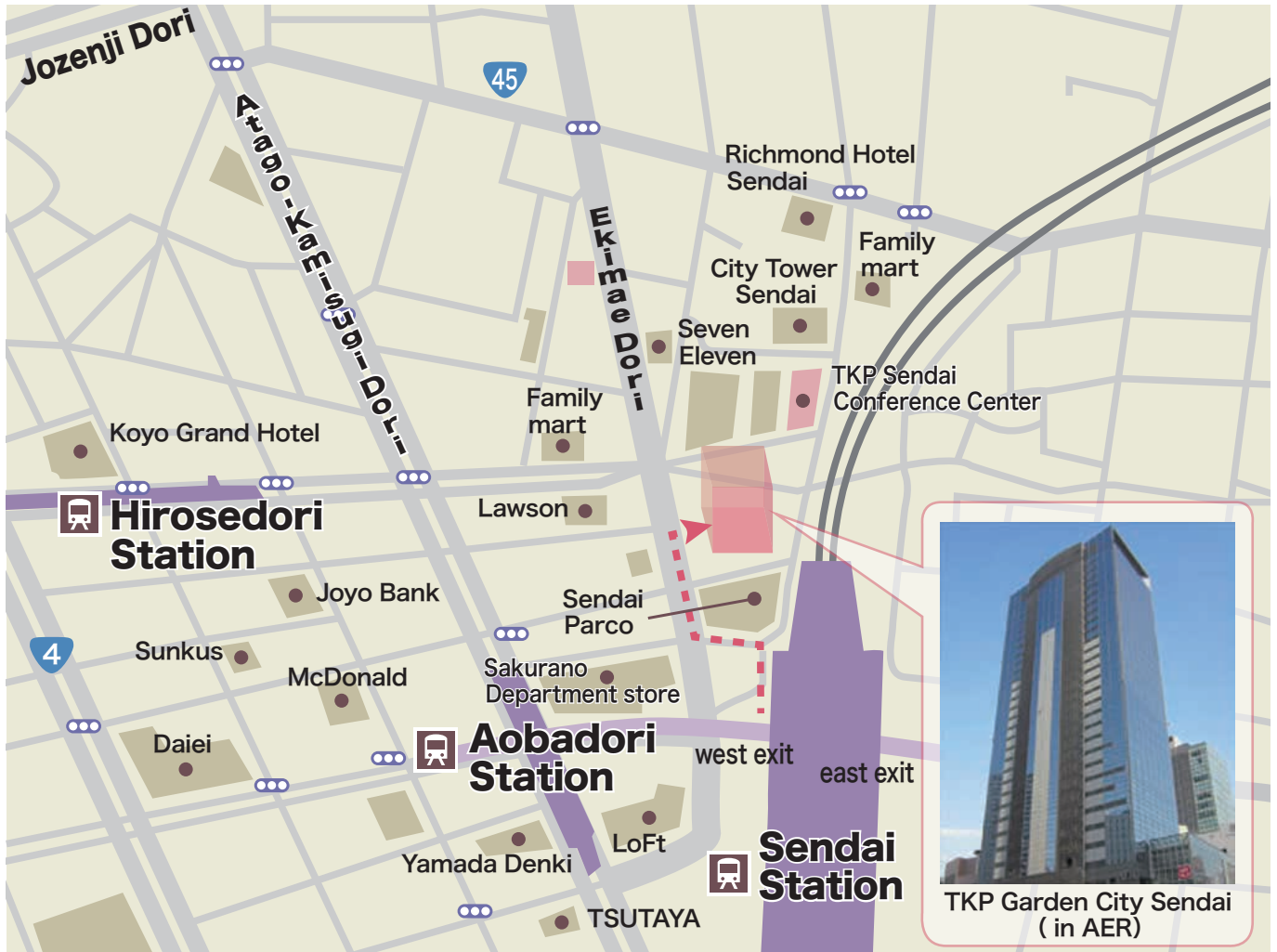私たちは今、世界のさまざまな国や地域で、予防から支援活動にわたる多様な医療ニーズと向き合っています。その一つひとつに答えていくことが、私たちの新たな使命。よりよい医薬品を待ち望んでいる人々に、少しでも早くお届けする。それが、いつまでも変わらない私たちの信念。

世界中の英知を集めて、タケダはこれからも全力で、医療の未来を切り拓いていきます。

武田薬品工業株式会社  
www.takeda.com/jp



## Access



Venue: TKP Garden City Sendai

AER 21F, Chuo, Aoba-ku, Sendai  
Tel: +81-22-714-8101

Duration:

Approx. 2 minutes walk from west exit, JR Sendai Station.